

Tissue Architecture Modification for Anterior Implant Esthetics: An Interdisciplinary Approach

Joseph Y K Kan, DDS, MS

Professor, Department of Restorative Dentistry, Advanced Education in Implant Dentistry, Loma Linda University School of Dentistry, Loma Linda, California, USA

Kitichai Rungcharassaeng, DDS, MS

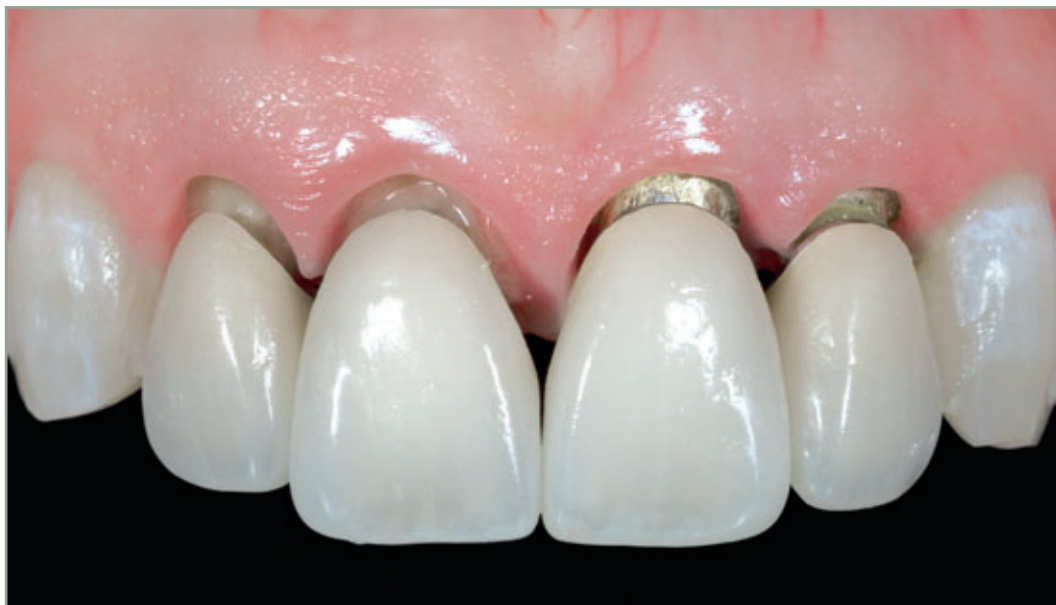Associate Professor, Department of Orthodontics and Dentofacial Orthopedics, Loma Linda University School of Dentistry, Loma Linda, California, USA

Michael Fillman, DDS, MS

Associate Professor, Department of Orthodontics and Dentofacial Orthopedics, Loma Linda University School of Dentistry, Loma Linda, California, USA

Joseph Caruso, DDS, MS, MPH

Chair and Associate Professor, Department of Orthodontics and Dentofacial Orthopedics, Loma Linda University School of Dentistry, Loma Linda, California, USA



Correspondence to: Dr Joseph Kan

Center for Prosthodontics and Implant Dentistry, Loma Linda University School of Dentistry, Loma Linda, CA 92354, U.S.A.;
phone: (011) 1-909-558-4980; fax: (011) 1-909-558-4803; e-mail: jkan@llu.edu

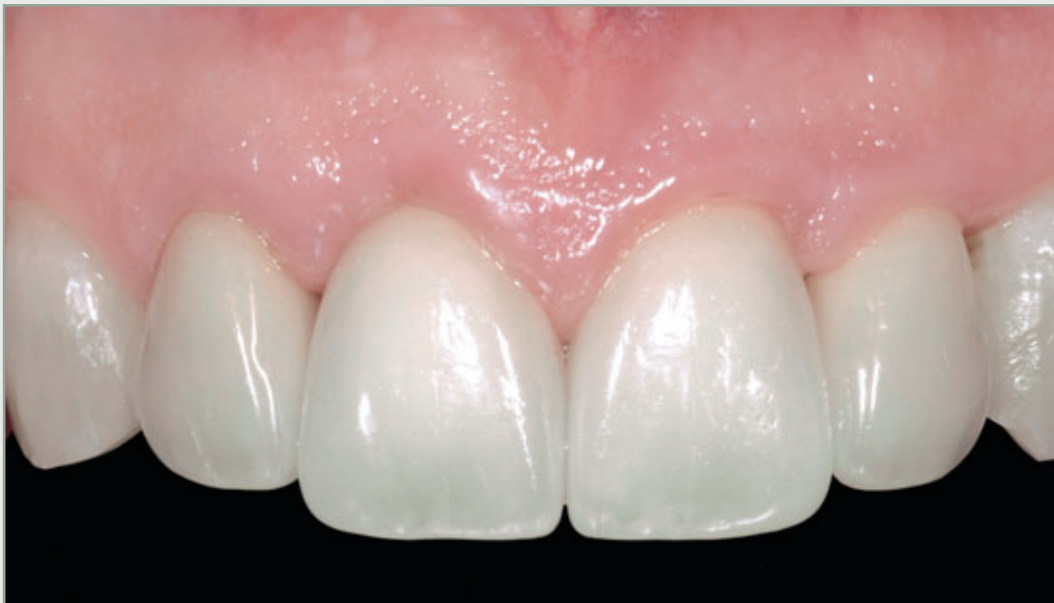

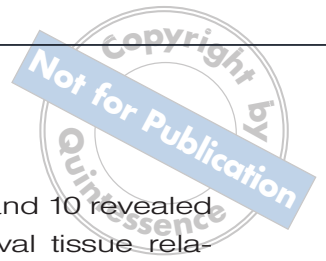
Abstract

Replacing multiple adjacent failing teeth with compromised osseous and gingival architecture with implants in the esthetic zone is often challenging and demanding for the clinician. Multiple procedures are usually required and entail a preservation technique, a re-creation approach, or a combination of both. This article describes

an interdisciplinary approach (orthodontics, periodontics, and prosthodontics) for tissue architecture modification in multiple adjacent failing teeth with osseous and gingival tissue discrepancies in the esthetic zone. The rationale and limitations are also discussed.

(Eur J Esthet Dent 2009;4:104–117.)





Introduction

In recent years, achieving optimal implant esthetics has been the Holy Grail of implant dentistry. As the peri-implant tissue architecture is the essence of the implant esthetics, techniques have been devised to preserve and/or re-create its natural form. To replace failing anterior maxillary teeth, the preservation technique (immediate implant placement and provisionalization) is usually the preferred method.¹⁻³ Nevertheless, it is indicated only with the presence of ideal pre-existing tissue conditions; eg, an appropriate gingival level and osseous-gingival relationship.¹ When tissue discrepancy is apparent, a re-creation approach, which entails periodontal and/or orthodontic intervention, might be required.⁴⁻⁶ This article describes an interdisciplinary approach for tissue architecture modification in multiple adjacent failing teeth with osseous and gingival tissue discrepancies in the esthetic zone. The rationale and limitations are also discussed.

Case presentation, treatment planning, and discussion

A 45-year-old female patient presented with discomfort on the left maxillary central and lateral incisors (teeth 9 and 10). Clinically, both teeth were presented with root caries, super-erupted and the facial free gingival margins were more than 2 mm apically positioned than that of the contralateral dentition (the right central and lateral incisors [teeth 7 and 8, Fig 1]). Furthermore, the lateral incisor was labially and distally displaced with Class II mobility. The presence of a thick periodontal biotype was apparent.

Bone sounding on teeth 9 and 10 revealed a low crest osseous-gingival tissue relationship facially (> 3 mm), and interproximally (> 4.5 mm) of the immediate adjacent dentition (teeth 8 and 11).⁷⁻⁹

The periapical radiograph displayed severe localized periodontal bone loss around the maxillary left central and lateral incisors (teeth 9 and 10), but with no periapical radiolucency (Fig 2). Upon occlusal examination, an excessive anterior vertical overlap (80%) was observed. In addition, a low incisal position of maxillary incisors and average gingival exposure were evident during smile analysis (Fig 3).¹⁰

The patient was advised that teeth 9 and 10 were hopeless and required extraction. The patient requested that the failing teeth be replaced with implant-supported restorations. The patient also expressed the desire to improve overall dental esthetics in the anterior region. After a thorough diagnosis and planning, a comprehensive treatment plan that addressed all the patient's concerns was devised. The treatment sequence entailed: (1) tissue architecture modification with orthodontic and periodontal intervention; (2) full coverage provisionalization of teeth 7 to 10 to determine appropriate esthetics, phonetics, and implant position; and (3) immediate implant placement and provisionalization of teeth 9 and 10.

Tissue architecture modification

A harmonious relationship between intra-oral components (tooth shape, size, shade, and position; and gingival architecture, level, and condition) and extra-oral components (active/inactive lip/smile lines) is fundamental to dental esthetics, and must



always be thoroughly evaluated during examination. The ability to identify the problems/challenges and to envision the treatment goal as well as the final outcome is an essential step in achieving anterior implant esthetics. Recognizing appropriate treatments and their limitations is also equally important. Therefore, in complicated situations, an interdisciplinary approach is, more often than not, warranted.

The patient presented with discrepancies at multiple levels: (1) incisal position to lip/smile line, (2) gingival level/architecture and tooth length, and (3) osseous–gingival relationship (Figs 1 to 3). Furthermore, these discrepancies were not uniformly expressed across the maxillary anterior teeth, warranting different/individualized managements/treatments on each involved tooth. The maxillary left incisors (teeth 9 and 10) were hopeless and were replaced with implant restorations, whereas only new restorations were needed for esthetic rehabilitation of maxillary right incisors (teeth 7 and 8). The maxillary canines (teeth 6 and 11) were in an acceptable condition both functionally and esthetically and did not require treatment.

Orthodontic procedure

Orthodontic treatment is the least invasive procedure for tissue architecture modification. Slow controlled vertical orthodontic tooth movement causes the entire attachment, which includes gingival and osseous tissues, to shift in unison with the tooth.^{11–14} As the patient's maxillary incisal level was low in relation to lip/smile line, especially at teeth 9 and 10, it seemed logical that orthodontic intrusion should be used to attain ideal incisal level. However, the gingival level of teeth 9 and 10 were significantly more apical when compared with that of con-

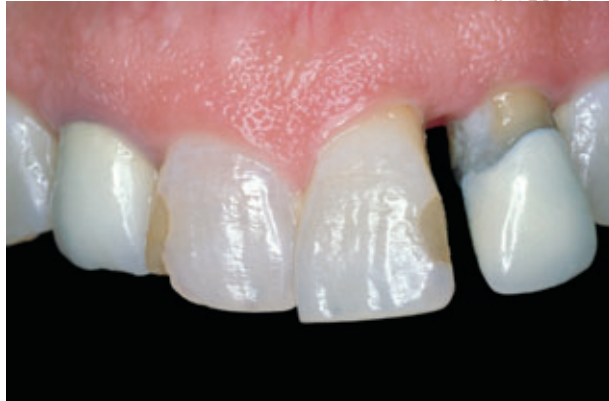

Fig 1 Facial view of failing maxillary left central and lateral incisors. Note the increased clinical crown length of the failing teeth due to super-eruption and gingival level discrepancy.

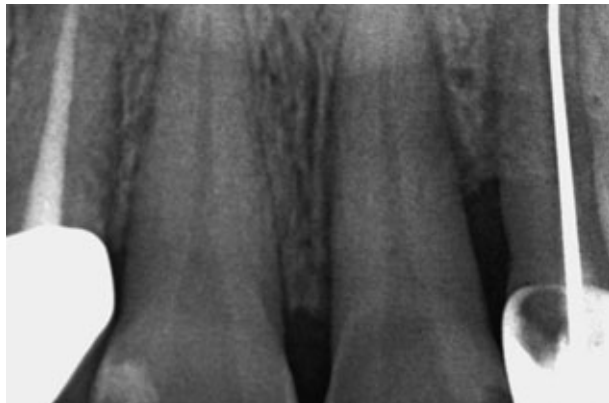


Fig 2 Periapical radiograph of failing maxillary left central and lateral incisors showing severe localized periodontal bone loss.

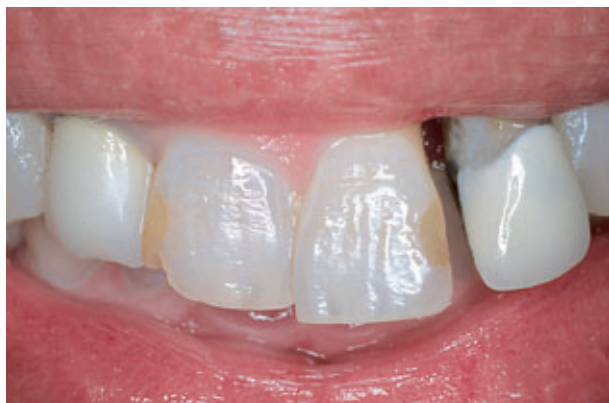

Fig 3 A low incisal position of maxillary incisors and average gingival exposure were evident during smile analysis.

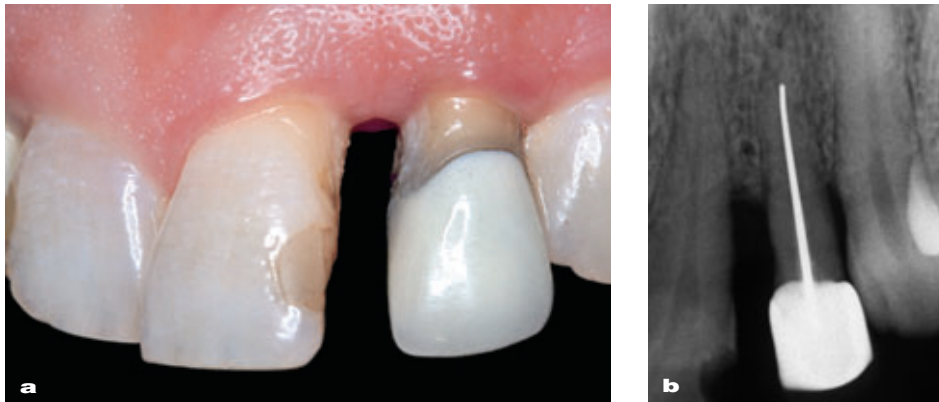
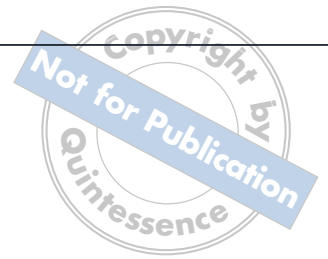

Fig 4 (a) Loss of interdental papilla between teeth 9 and 10 due to (b) extensive horizontal bone loss and increased inter-radicular space.

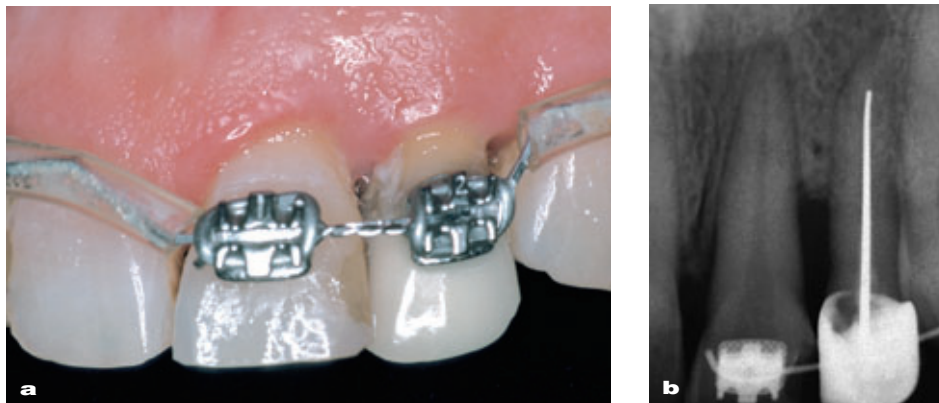


Fig 5 (a) Space closure of teeth 9 and 10 using an elastomeric chain improved the height of the interdental papilla and (b) created a more favorable condition for orthodontic tooth extrusion. Note the root parallelism after space closure.

tralateral dentition. Furthermore, a low-crest osseous–gingival relationship (> 4.5 mm) was observed at teeth 9 and 10. Since 9 and 10 were to be replaced with implants, the goal was to create an optimal osseous and gingival condition for immediate implant placement and provisionalization (preservation approach). Orthodontic intrusion of teeth 9 and 10 would have resulted in greater tissue discrepancies. Therefore, orthodontic extrusion of teeth 9 and 10 and

minimal intrusion of tooth 8 were optimal treatments in this situation.

While the facial tissue improvement by orthodontic extrusion has been well documented,^{11,15-17} similar results have not been replicated for the interproximal tissue. Therefore, prior to vertical orthodontic tooth movement, the involved teeth should first be aligned in appropriate horizontal positions. In the presented situation, there was a large inter-radicular space between teeth 9 and

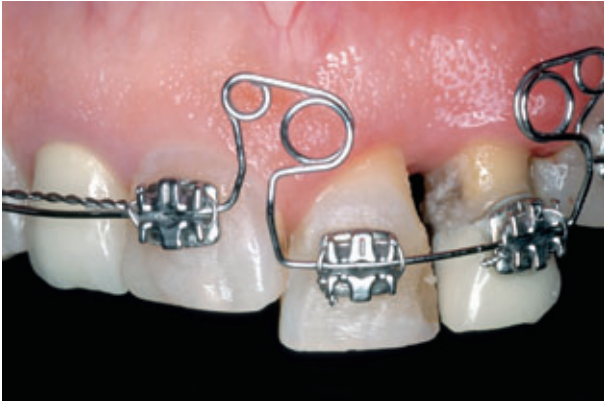

Fig 6 Orthodontic extrusion of teeth 9 and 10. The multiple-loop design provides light continuous extrusive force and direction control.

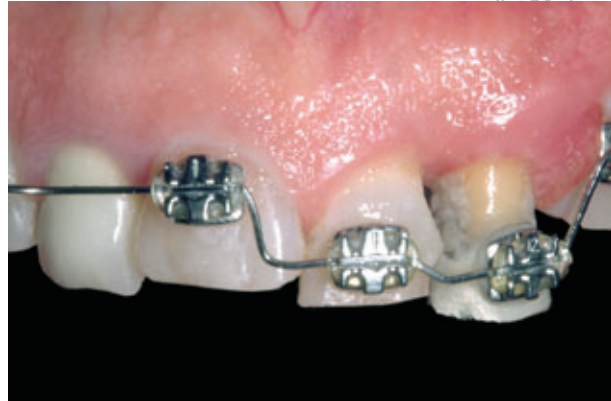

Fig 7 More extrusion of tooth 10 was carried out as planned along with intrusion of tooth 8. The incisal edges of the extruded teeth were adjusted periodically to avoid occlusal interference.

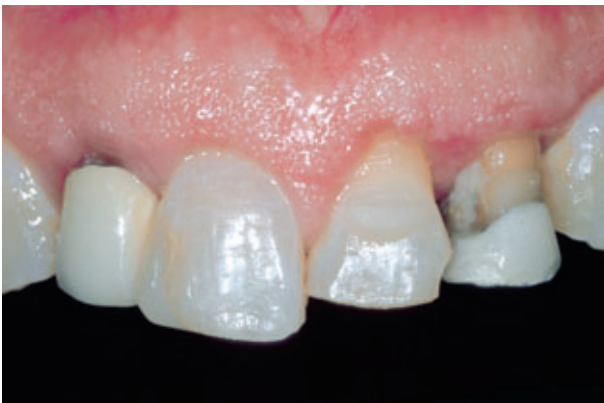

Fig 8 Orthodontic appliances were removed after an 8-month period of stabilization. Minor gingivectomy was performed for esthetic reasons. While the results from orthodontic extrusion (teeth 9 and 10) were stable, some relapse was observed with the intruded tooth (tooth 8).

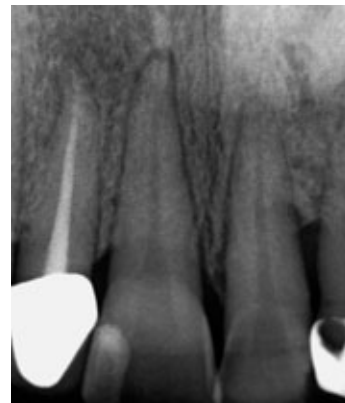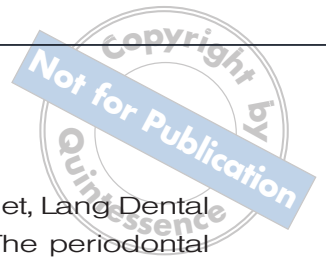


Fig 9 Periapical radiograph after orthodontic treatment. Note the coronal osseous migration of bone around teeth 9 and 10.

10, possibly due to a periodontal problem and/or trauma from occlusion (Figs 4a and b). Interproximal bone in such a situation does not seem to respond well to vertical orthodontic tooth movement. Not only did the space closure of teeth 9 and 10 using an elastomeric chain improve the height of the interdental papilla, it also created a more favorable condition for orthodontic tooth extrusion (Figs 5a and b). Root parallelism should also be observed before orthodon-

tic tooth extrusion is performed to allow for a predictable direction of tooth movement and osseous tissue migration (Fig 5b).

It should be noted that the primary objective of tissue architecture modification by orthodontic intervention is to attain an ideal osseous level rather than a gingival level (Figs 6 and 7). Since the osseous-gingival relationship remains fairly constant after orthodontic extrusion, and the initial osseous-gingival relationship is known



(measured through bone sounding), the approximate osseous level can be calculated from the gingival level. Overtreatment is, however, recommended to compensate for potential tissue loss during subsequent surgeries. Once the desired gingival tissue level was reached, the involved teeth were stabilized for 8 months with a non-active orthodontic appliance. Although 4 weeks to 6 months of retention time has been recommended,^{11,18-20} it is the authors' opinion and clinical experience that a minimal retention time of 6 to 8 months be enforced in this kind of situation. This long (> 6 months) stabilization period allows for the maturation of the evaginated gingival tissue as well as the repositioned osseous tissue. Nevertheless, while the results from orthodontic extrusion were stable, some relapse could be observed with the intruded tooth 8 (Fig 8). This phenomenon must be taken into consideration during treatment planning and retention.

Periodontal crown lengthening and provisionalization

While the osseous tissue discrepancies can be resolved by orthodontic intervention, the optimal gingival architecture is generally accomplished with delicate periodontal plastic procedures (Fig 9). Following the completion of orthodontic therapy, a diagnostic impression was made to prepare teeth 7 to 10 for crown lengthening surgery and provisional restorations. A diagnostic waxup was first performed on teeth 7 to 10 to create the desirable gingival outline, levels, tooth contours, and incisal edge positions. The cast was then duplicated and a full contour silicone matrix (Sil-Tech, Ivoclar North America Amherst, NY, USA) was made for the fabrication of the periodontal surgical guide using auto-

polymerizing acrylic resin (Jet, Lang Dental MFG, Wheeling, IL, USA). The periodontal surgical guide outlined the pre-determined free gingival margin of the definitive restorations indicated by the diagnostic wax patterns. In addition, the silicone matrix was also used as a guide to form the contour of acrylic resin provisional shells (teeth 7 to 10). The provisional shells were fabricated by initially lining them with autopolymerizing acrylic resin (Jet, Lang Dental MFG) for resiliency and were subsequently overlaid with light polymerizing acrylic resin (Gradia™, GC America, Alsip, IL, USA) for esthetics.

Following the administration of local anesthesia, the facial gingiva around teeth 7 to 10 was first re-contoured using a #15c blade (Kei, Japan) with the aid of the periodontal surgical guide (Fig 10). While an inverse bevel incision^{21,22} around the free gingival margin is recommended for conventional crown lengthening procedures (teeth 7 and 8) to improve marginal adaptation, in the authors' opinion, a butt joint incision is more advantageous when preparing the gingiva for implant placement (teeth 9 and 10), as it minimizes the thinning of the facial gingival tissue, which may increase the risk of peri-implant gingival recession.⁸

The detrimental effects of biologic width violation from improper placement of restoration margin have been suggested.^{23,24} Therefore, to establish a healthy biologic width during the crown lengthening procedure of teeth 7 and 8, an apicocoronal distance of 2.5 to 3 mm between the facial bone and the margin of the provisional restoration must be accomplished (Fig 11).²⁵⁻²⁷ On the other hand, upon bone sounding, a high crest situation (< 3 mm bone-gingiva relationship) was observed

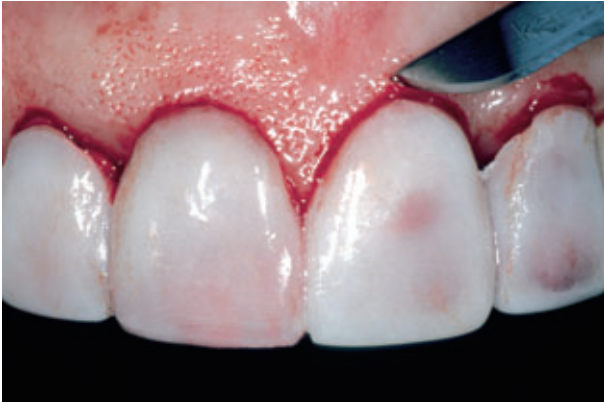

Fig 10 Esthetic facial gingiva recontouring using a #15 blade and using the periodontal surgical guide outlining the pre-determined free gingival margin of the definitive restorations indicated by the diagnostic wax patterns.

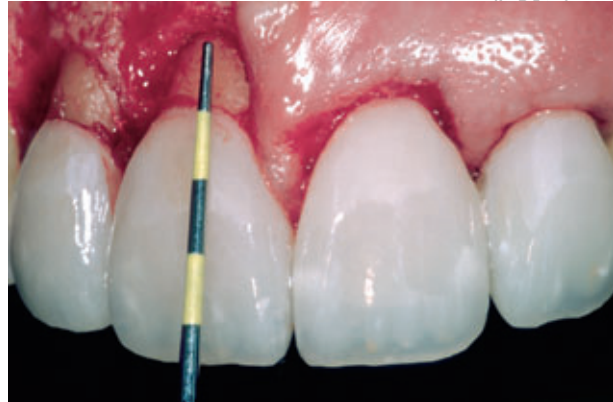

Fig 11 To establish a healthy biologic width, during the crown lengthening procedure of teeth 7 and 8, an apicoronal distance of 3 mm between the facial bone and the provisional restoration margin of teeth 7 and 8 was accomplished.

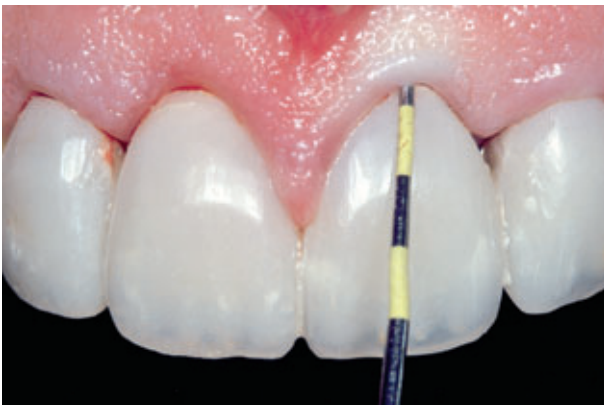

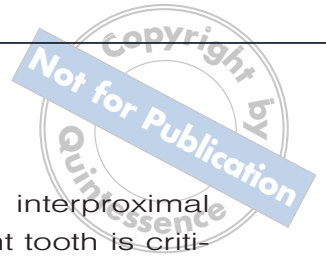
Fig 12 High crest (< 3 mm osseous-gingiva relationship) was noted on the facial aspect of tooth 9 as a result of orthodontic tooth extrusion and gingival re-contouring.

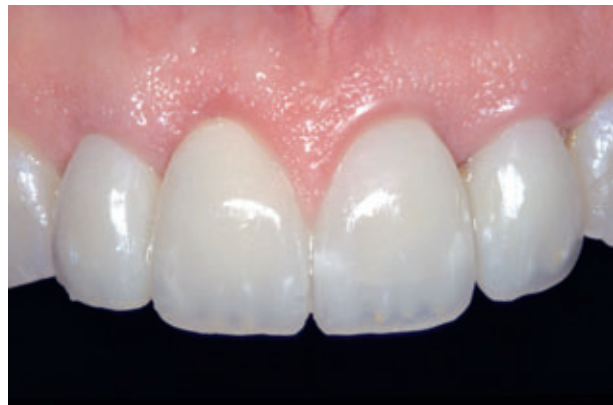

Fig 13 After 2 months of healing, an acceptable level of gingival esthetic was observed.

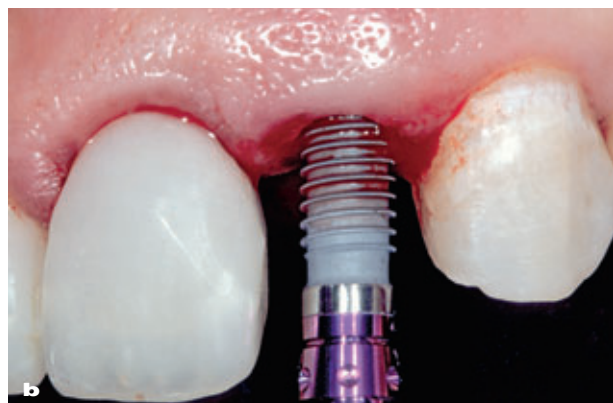
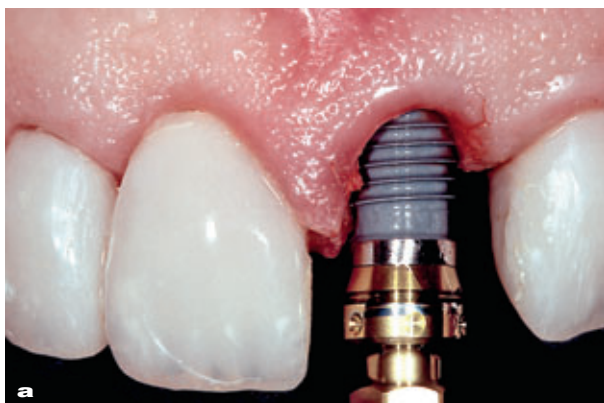
Fig 14 Immediate implant placement of maxillary left (a) central incisor (9) and (b) lateral incisor (10).



on the facial aspect of failing teeth 9 and 10. (Fig 12). This favorable condition was the result of tissue architecture modification via a combination of orthodontic tooth extrusion and gingival re-contouring. As labial bone developed by orthodontic extrusion is often thin and is prone to resorption following flap surgeries,^{28,29} flap reflection was avoided on teeth 9 and 10. The facial high crest situation of teeth 9 and 10, along with the flapless procedure,³⁰ may mitigate the inherent facial bone resorption and gingival recession often encountered with immediate implant placement and provisionalization procedures.

Teeth 7 to 10 were then prepared for metal-ceramic restorations. The provisional shells were then re-lined with autopolymerizing acrylic resin (Jet, Lang Dental MFG), and cemented with temporary cement (Temp-Bond™, Kerr, Orange, CA, USA). The gingiva was allowed to heal for 6 months,²⁵ at which point the patient was re-evaluated for periodontal and esthetic status to determine if more reconstructive procedures were required. An acceptable esthetics and osseous-gingiva relationship was observed, prompting immediate implant placement and provisionalization at the subsequent treatment (Fig 13).


Tissue preservation procedure

Immediate implant placement and provisionalization has been shown to be an effective preservative procedure, especially in the single failing tooth situation in the esthetic zone.^{2,3,31,32} The surgical aspect of this technique, which involves atraumatic tooth extraction, flapless surgery, and immediate implant placement, is intended for osseous preservation. Likewise, immediate artificial tooth replacement aims to maintain the gingival tissue.¹ For

single tooth replacement, interproximal bone level on the adjacent tooth is critical to the maintenance of the interproximal papilla.⁸ In multiple adjacent failing teeth situations, it has been suggested that immediate implant placement and provisionalization should be done in an alternate manner (one carried out after the other implant has completely integrated).³³ The alternate approach avoids simultaneous extraction of multiple adjacent teeth, which may compromise the integrity and stability of the interproximal bone and papilla, as well as maintain the proximal bone on one side of the implant while the other side is healing. In the patient situation presented, since the treatment was rendered prior to the conception of the alternate approach, both failing teeth (9 and 10) were removed simultaneously with immediate tooth replacement. Fortunately, the stability of interproximal bone and papilla between teeth 9 and 10 was observed throughout the provisionalization period (6 months after periodontal tissue architecture modification; 14 months after orthodontic intervention). In addition, the minimal root structure remaining in the socket following orthodontic procedure would render extraction minimally traumatic to the interproximal bone and papilla. Nevertheless, the alternate approach should always be considered as an option, especially in thin biotype situations.

Preparation of surgical template and provisional prosthesis

Prior to implant surgery, provisional shells of teeth 9 and 10 were fabricated using a combination of autopolymerizing (Jet, Lang Dental MFG) and light-cured acrylic resin (Gradia, GC America). The implant



dimensions were selected with the aid of the periapical radiograph and study cast. The implant length was estimated by measuring from the desired cervical depth of the implant (~3 mm apical to the pre-determined free gingival margin of the definitive restoration).⁹ The implant platform diameter should correspond to or be slightly less than the dimension of the failing tooth at the desired cervical depth, to allow for a minimal distance of 2.0 mm between the implant and adjacent teeth and 3.0 mm between adjacent implants to minimize marginal bone loss due to encroachment.^{34,35} A surgical template was fabricated to identify the pre-determined facial gingival margin.

Immediate implant placement and provisionalization

After administration of local anesthesia, the remaining tooth structures of 9 and 10 were removed atraumatically with the aid of the periosteal elevator (Nobel Biocare, Yorba Linda, CA, USA). A periodontal probe was used to verify the integrity of the labial bone of the extraction sockets. Implant osteotomies for teeth 9 and 10 were sequentially prepared to completion (manufacturer's recommendation, Replace[®], Nobel Biocare), and the socket was thoroughly debrided with normal saline rinse before the implants (Replace, Nobel Biocare) were inserted with 35 Ncm torque (Figs 14a and b). After the titanium temporary abutment (Replace, Nobel Biocare) was hand tightened onto the implant, low viscosity flowable light-cured polymerizing resin (Revolution[™], Kerr) was applied subgingivally to capture the cervical gingival emergence of the extracted teeth. The coronal portions of the customized temporary abutments were then prepared extra-orally for appropriate

retention and resistance form. After the provisional restorations were re-lined to retrofit onto the abutments, they were adjusted to clear all centric and eccentric functional contacts and were subsequently cemented with provisional cement (Temp-bond, Kerr) (Fig 15). Periapical radiographs were made to verify the fit of the abutments and the provisional prosthesis as well as complete removal of the provisional cements (Fig 16).

Appropriate antibiotic and analgesic were prescribed for postoperative use. The patient was instructed not to brush the surgical site, but rinse gently with 0.12% chlorhexidine gluconate (Peridex, Procter & Gamble, Cincinnati, OH, USA). The patient was advised against any activities that might compromise the surgical site. A liquid diet during the first week and a soft diet for the remaining duration of the implant-healing phase were recommended.

Definitive restoration

The gingival architecture around implant 9 and 10 was well preserved after 8 months following implant surgery (Fig 17). The definitive impression for metal-ceramic crowns (7 and 8) and implants 9 and 10 was made using vinyl poly-siloxane (Aquasil[™] Monophase, Dentsply Caulk, Milford, IL, USA). A hexed direct abutment (Replace, Nobel Biocare) was waxed and cast in type IV gold (Monogram IV, Leach & Dillon, Cranston, RI, USA), duplicating the gingival emergence established by the customized temporary abutment. The finished abutments were torqued to 35 Ncm (manufacturer's recommendation, Nobel Biocare) and the definitive metal-ceramic restorations (Creation[®], Jensen, North Haven, CT, USA) were cemented with permanent cement (RelyX[™], 3M, St. Paul, MN, USA)

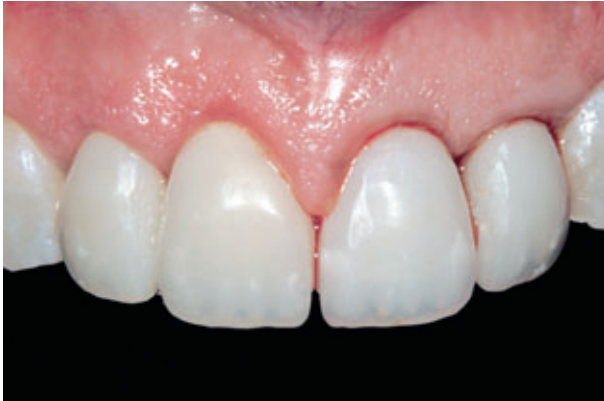

Fig 15 Provisionalization of teeth 9 and 10 immediately following implant placement.

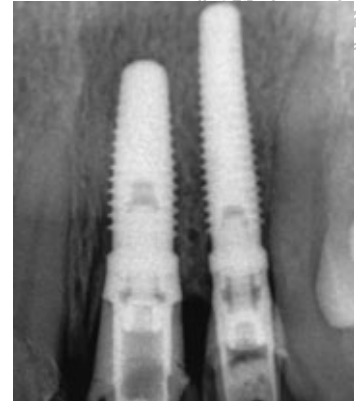

Fig 16 Periapical radiograph of immediate implant placement and provisionalization of teeth 9 and 10 at the day of surgery.

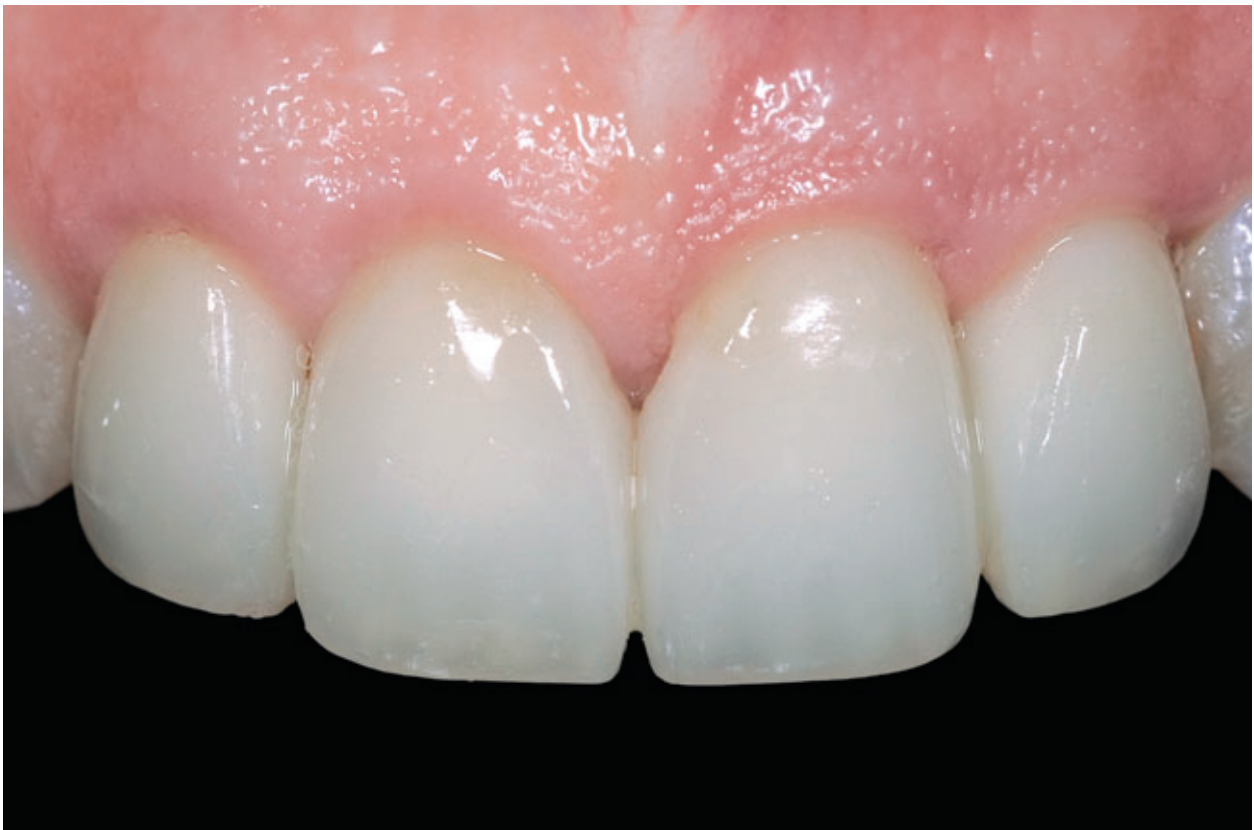

Fig 17 Well preserved gingival architecture around implants 9 and 10, eight months after implant placement.

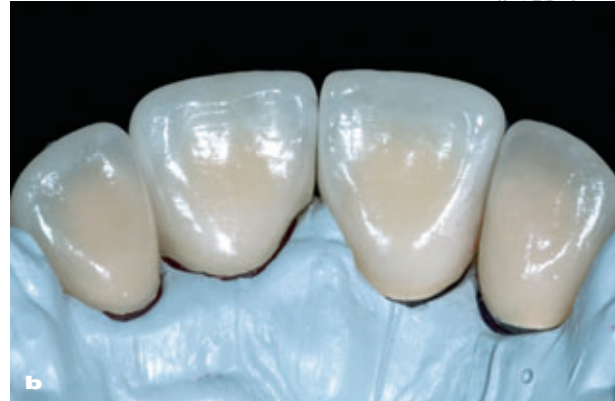
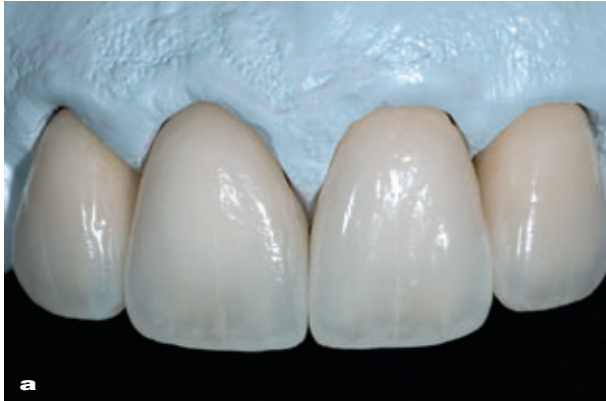
Fig 18 (a) Facial and (b) palatal views of the definitive restorations.

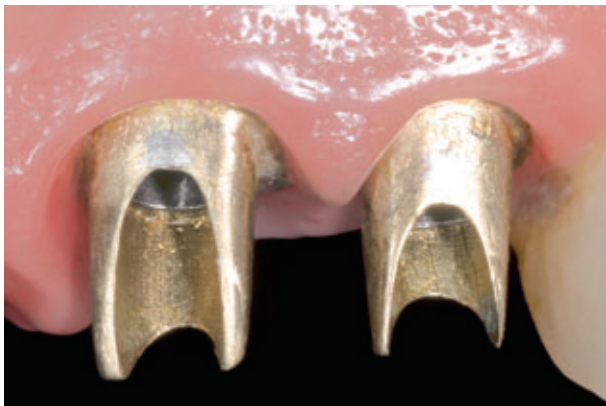

Fig 19 The custom gold alloy abutments were torqued to 35 Ncm.

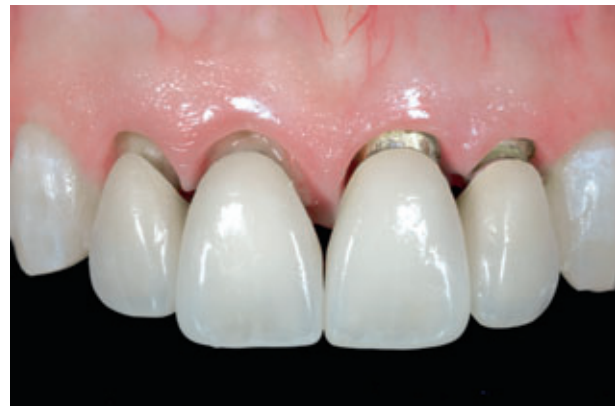

Fig 20 Healthy and well-developed gingival architecture presents an optimal recipient site for definitive metal-ceramic restorations 8 months following implant surgery.

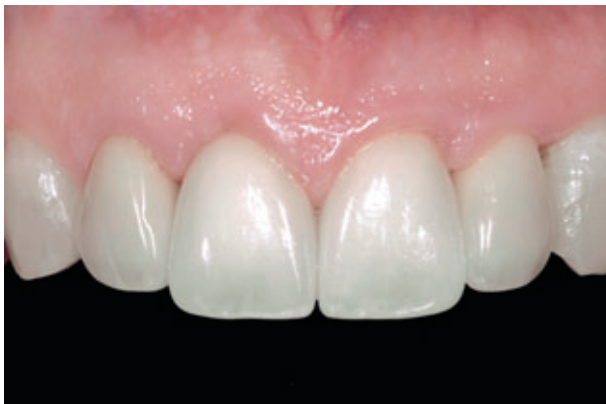

Fig 21 Facial view of definitive restorations at time of placement.

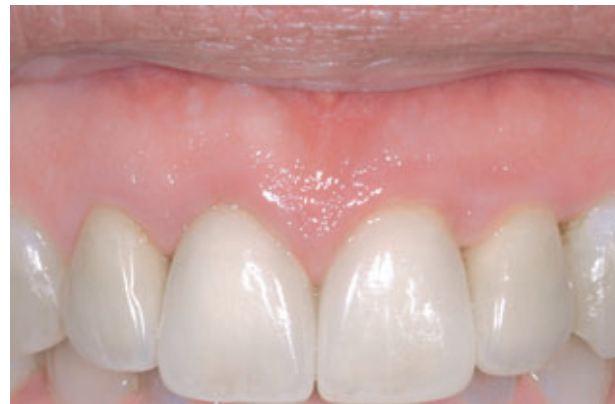

Fig 22 A significantly higher smile line and more harmonious gingival architecture following esthetic reconstruction of maxillary anterior teeth were apparent compared with initial smile examination.

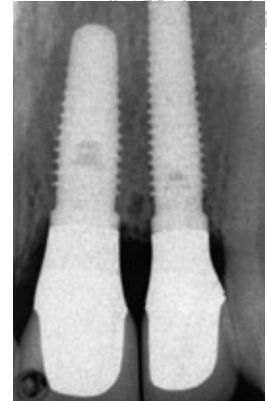
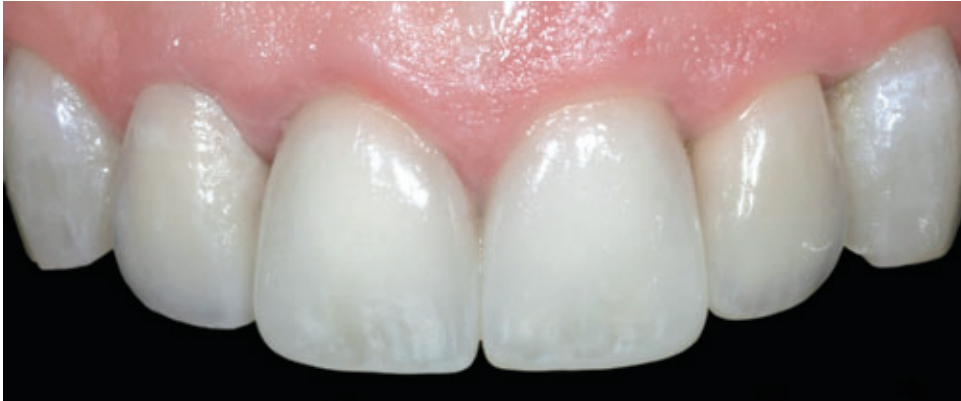

Fig 23 Facial view of the definitive restorations at 7 years follow-up.

Fig 24 Periapical radiograph of definitive restorations at 7 years.

(Figs 18 to 22). Clinical and radiographic follow-up at 7 years showed a stable gingival architecture around restorations on both natural dentition and implants (Figs 23 and 24).

Conclusions

Achieving anterior dental esthetics requires not only the understanding of the anatomy of the hard and soft tissues/organs involved, but also their physiology and interwoven dynamics when subjected to different treatments. While proper diagnosis and treatment planning as well as precise execution of the treatment are important for the interdisciplinary approach, it is the good communication and rapport among the specialists that is the key to the success of the final outcome.

Acknowledgements

The authors declare no financial interests in any of the products cited within this article. Dr Kan is grateful to the master ceramist, Hatate Katsuhiko RDT, for the fabrication of the definitive restorations displayed in this article.

References

1. Kan JY, Rungcharassaeng K. Site Development for Anterior Single Implant Esthetics: The Dentulous Site. *Compend Contin Educ Dent* 2001;22:221–232.
2. Kan JY, Rungcharassaeng K. Immediate placement and provisionalization of maxillary anterior single implants: a surgical and prosthodontic rationale. *Pract Periodontics Aesthet Dent* 2000;12:817–824.
3. Kan JY, Rungcharassaeng K, Lozada JL. Immediate placement and provisionalization of maxillary anterior single implants: 1-year prospective study. *Int J Oral Maxillofac Implants* 2003;18:31–39.
4. Spears FM, Kokich VG, Mathews DP. Interdisciplinary management of anterior dental esthetics. *J Am Dent Assoc* 2006;137:160–169.



5. Mathews DP. Soft tissue management around implants in the esthetic zone. *Int J Periodontics Restorative Dent* 2000;20:141–149.
6. Mathews DP. The pediculated connective tissue graft: A technique for improving unaesthetic implant restorations. *Pract Proced Aesthet Dent* 2002;14:719–724.
7. Kois J. Altering gingival levels: The restorative connection, Part I: Biologic variables. *J Esthet Dent* 1994;6:3–9.
8. Kan JY, Rungcharassaeng K, Umezu K, Kois JC. Dimensions of peri-implant mucosa: An evaluation of maxillary anterior single implants in humans. *J Periodontol* 2003;74:557–562.
9. Kois J, Kan JY. Predictable peri-implant gingival aesthetics: Surgical and prosthetic rationales. *Pract Proced Aesthet Dent* 2001;13:691–698.
10. Tjan AH, Miller GD, The JG. Some esthetic factors in a smile. *J Prosthet Dent* 1984;51:24–28.
11. Reitan K. Clinical and histologic observations on tooth movement during and after orthodontic treatment. *Am J Orthod* 1967;53:721–745.
12. Stern N, Becker A. Forced eruption: Biological and clinical considerations. *J Oral Rehabil* 1980;7:395–402.
13. Linde J. *Textbook of Clinical Periodontology*. Copenhagen, Denmark: Munksgaard, 1983.
14. Buskin R, Castellon P, Hochstedler JL. Orthodontic extrusion and orthodontic extraction in preprosthetic treatment using implant therapy. *Pract Periodontics Aesthet Dent* 2000;12:213–219.
15. Salama H, Salama M, Kelly J. The orthodontic-periodontal connection in implant site development. *Pract Periodontics Aesthet Dent* 1996;8:923–932.
16. Levine RA. Force eruption in the esthetic zone. *Compend Contin Educ Dent* 1997;18:795–804.
17. Celenza F. Orthodontically induced gingival and alveolar augmentation: Clinical and histological findings. *Pract Proced Aesthet Dent* 2001;13:173–175.
18. Ingber JS. Forced eruption: Alteration of soft tissue cosmetic deformities. *Int J Periodontics Restorative Dent* 1989;9:417–425.
19. Mantzikos T, Shamus I. Case report: Forced eruption and implant site development. *Angle Orthod* 1998;68:179–186.
20. Park YS, Yi KY, Moon SC, Jung YC. Immediate loading of an implant following implant site development using forced eruption: A case report. *Int J Oral Maxillofac Implants* 2005;20:621–626.
21. Litch JM, O'Leary TJ, Kafrawy AH. Pocket epithelial removal via crestal and subcrestal scalloped internal bevel incisions. *J Periodontol* 1984;55:142–148.
22. Fisher MR, Bowers FM, Bergquist JJ. Effectiveness of the reverse bevel incision used in the modified Widman procedure in removing pocket epithelium in humans. *Int J Periodontics Restorative Dent* 1982;2:32–43.
23. Reeves WG. Restorative margin placement and periodontal health. *J Prosthet Dent* 1991;66:733–736.
24. Tarnow D, Stahl SS, Magner A, Zamzok J. Human gingival attachment responses to subgingival crown placement. Marginal remodelling. *J Clin Periodontol* 1986;13:563–569.
25. Bragger U, Lauchenauer D, Lang NP. Surgical lengthening of the clinical crown. *J Clin Periodontol* 1992;19:58–63.
26. Pontoriero R, Carnevale G. Surgical crown lengthening: A 12-month clinical wound healing study. *J Periodontol* 2001;72:841–848.
27. Lanning SK, Waldrop TC, Gunsolley JC, Maynard JG. Surgical crown lengthening: Evaluation of the biological width. *J Periodontol* 2003;74:468–474.
28. Pennel BM, King KO, Wilderman MN, Barron JM. Repair of the alveolar process following osseous surgery. *J Periodontol* 1967;38:426–431.
29. Wilderman MN, Pennel BM, King K, Barron JM. Histogenesis of repair following osseous surgery. *J Periodontol* 1970;41:551–565.
30. Kan JY, Rungcharassaeng K, Ojano M, Goodacre CJ. Flapless Anterior Implant Surgery: A Surgical and Prosthodontic Rationale. *Pract Periodontics Aesthet Dent* 2000;12:467–474.
31. Wohrle PS. Single-tooth replacement in the aesthetic zone with immediate provisionalization: Fourteen consecutive case reports. *Pract Periodontics Aesthet Dent* 1998;10:1107–1114.
32. Kan JY, Rungcharassaeng K, Lozada JL. Bilaminar subepithelial connective tissue grafts for immediate implant placement and provisionalization in the esthetic zone. *J Calif Dent Assoc* 2005;33:865–671.
33. Kan JY, Rungcharassaeng K. Interimplant papilla preservation in the esthetic zone: a report of six consecutive cases. *Int J Periodontics Restorative Dent* 2003;23:249–259.
34. Esposito M, Ekkestubbe A, Grondahl K. Radiological evaluation of marginal bone loss at tooth surfaces facing single Branemark implants. *Clin Oral Implants Res* 1993;4:151–157.
35. Tarnow DP, Cho SC, Wallace SS. The effect of inter-implant distance on the height of inter-implant bone crest. *J Periodontol*. 2000;71:546–549.