

Computer-Guided Implant Treatment with All-on-Four Immediate-Function Concept



Joseph Y.K. Kan, DDS, MS
Professor
Advanced Education in
Implant Dentistry
Loma Linda University
School of Dentistry
Loma Linda, California
Phone: 909.558.4980
Email: jkan@llu.edu



Kitichai Rungcharassaeng, DDS, MS
Associate Professor
Department of Orthodontics and
Dentofacial Orthopedics
Loma Linda University
School of Dentistry
Loma Linda, California
Phone: 909.558.4604
Email: krungcharassaeng@llu.edu



Kotaro Oyama, DDS
Graduate Student
Advanced Education in
Implant Dentistry
Loma Linda University
School of Dentistry
Loma Linda, California
Phone: 909.558.4980
Email: kotarooyama@aol.com

Abstract

Computer-guided implant treatment continues to grow in popularity. Published reports show its successful use in conjunction with immediately loaded implant prostheses. The All-on-Four concept entails placement of 4 implants to support a fixed complete denture with the most distal implants in a tilted trajectory to minimize the cantilever length. This article describes the procedures involved in computer-guided implant treatment with the All-on-Four immediate-function concept.

Learning Objectives

After reading this article, the reader should be able to:

- describe the procedures involved in computer-guided implant treatment.
- identify optimal implant positions for immediately loaded, fixed complete dentures and accurately execute the plan with a computer-guided surgical template.
- discuss the All-on-Four immediate-function concept.

The immediate loading of implant-supported fixed complete dentures has been well documented with high success rates in edentulous maxillas and mandibles.¹⁻⁵ To avoid extensive surgeries (ie, maxillary sinus augmentation or nerve repositioning), 4 to 6 implants are usually placed in the anterior region of the jaws; however, this implant distribution often results in long posterior cantilever length that is biomechanically unfavorable, especially in immediate-loading situations. A modification that includes the placement of the most distal implants in a tilted trajectory to minimize the cantilever length has been advocated.^{6,7} The technique of tilting the most distal implants can be implemented whether the clinician chooses immediate or delayed implant loading. However, studies of the immediate-function concept, which entails simultaneous placement of implants, abut-

ments, and restorations (provisional or definitive), show promising results with few complications.⁸⁻¹³

Combining these 2 concepts, the All-on-Four immediate-function concept is a simple, safe, and effective surgical and prosthetic protocol for immediate function (within 2 hours) of 4 implants supporting a fixed prosthesis in a completely edentulous mandible.^{14,15} While the All-on-Four immediate-function concept can be used with or without computer-guided technology, the advent of 3-dimensional (3D) computer-guided technology optimizes implant treatment planning, allowing accurate and minimally invasive surgical procedures to be rendered. Recently, Malo and colleagues first evaluated and reported the integration of the All-on-Four immediate-function concept with computer-guided implant placement for the rehabilitation of completely edentulous jaws.¹⁶ The preliminary results showed that this

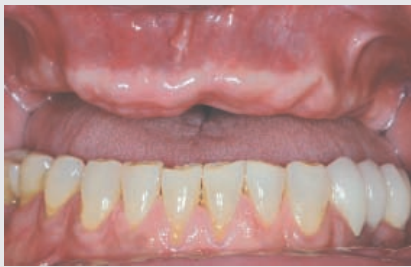

Figure 1—Preoperative intraoral view showing edentulous maxilla.

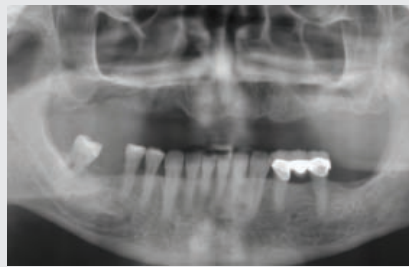

Figure 2—Preoperative panoramic radiograph.

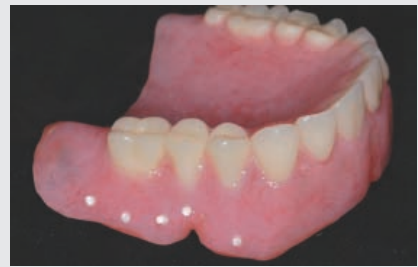

Figure 3—Radiopaque markers in the facial flange of the maxillary denture.

treatment modality can be predictable with a high implant survival rate.

This article describes the procedures involved in delivering immediately loaded, fixed complete dentures using a computer-guided surgical template (NobelGuide, Nobel Biocare) with the All-on-Four immediate-function concept.

Case Presentation

A 63-year-old man presented with a completely edentulous maxilla and partially edentulous mandible (Figures 1 and 2). A treatment plan that included an implant-supported maxillary fixed complete denture, extraction of tooth No. 31, and a single implant crown on tooth No. 30 was presented to the patient. The patient agreed and consented to the treatment plan.

CT Scan and 3D Image-Based Treatment Planning

A definitive maxillary denture was fabricated with the appropriate function and esthetics to serve as a template for the computer-guided surgery. Ten radiopaque markers (Hygenic Temporary Dental Stopping, Coltène/Whaledent Inc), 1.5 mm in diameter and 1 mm in depth, were placed in the facial flange of the maxil-

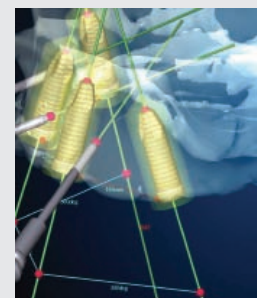
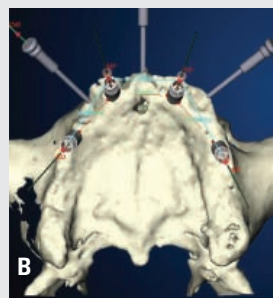


Figure 4—Simulation of implant and anchor pin placement using the 3D Procera Software Planning Program: (A) occlusal view; (B) lateral view. Note the tilting of the posterior implants to bypass the maxillary sinuses. The posterior implants were angulated less than 30°. Guided anchor pins were planned in a tripod configuration.

lary denture (Figure 3). A centric occlusion index made of a rigid vinyl polysiloxane interocclusal record material (Exabite II NDS, GC America, Inc) was fabricated to stabilize the denture against the opposing dentition during the computed tomography (CT) scan.

The patient received a CT scan (LightSpeed VCT, GE Healthcare) using the double-scan technique. The first scan was made with the patient wearing the maxillary denture with the radiopaque markers. The second scan was performed with the denture alone in the same orientation as it was during the first scan.

The digital imaging and communication in medicine (DICOM) data of the 2 sets of scans were transferred to the 3D Procera Software Planning program (Nobel Biocare) and super-

imposed on each other. This program allowed the clinician to evaluate the osseous tissue in relation to the position of the denture and plan the number, length, position, and angulations of the implants and anchor pins. A total of 4 implants were planned in the positions of teeth Nos. 5, 7, 10, and 12 (NobelSpeedy Replace, Nobel Biocare) in which the implants for teeth Nos. 5 and 12 were intentionally tilted distally to avoid the maxillary sinuses (Figures 4A and 4B).

The degree of distal implant tilting will determine the type of prosthesis and prosthetic components involved. When compensating for a long distal cantilever, a distal implant trajectory of up to 45° is acceptable. In such situations, 30°-angulated multi-unit abutments (Nobel Biocare) are used

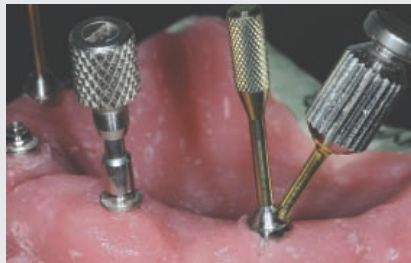

Figure 5—Straight and 30°-angulated non-engaging multiunit abutments were connected to the anterior and posterior implant replicas respectively. Note the amount of angulation compensation of the posterior implant.

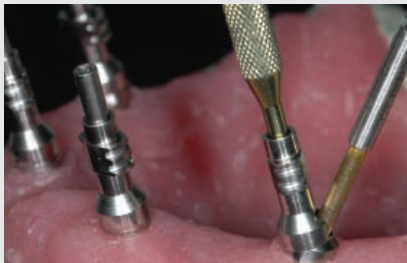


Figure 6—The impression copings were connected to the anterior straight multiunit abutments and the jig stabilizers were connected to the posterior angulated multiunit abutments.



Figure 7—An acrylic resin jig between the anterior straight multiunit abutment and posterior angulated abutment was fabricated for proper abutment orientation transfer from extraoral preparation to intraoral setting.

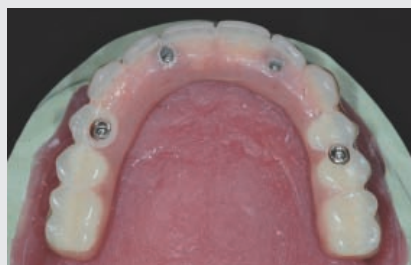

Figure 8—All-resin prosthesis. Note the anterior temporary copings integrated with the resin prosthesis. The posterior copings were not included in the prosthesis and would be picked up and incorporated into the prosthesis intraorally at the time of prosthesis placement.

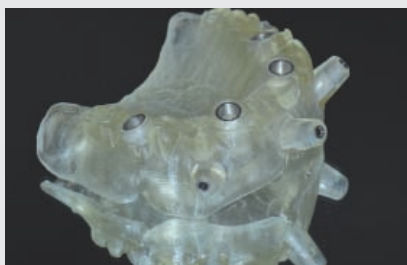


Figure 9—The stereolithographic surgical template.

on the distal implants to allow for easy prosthetic screw access and prosthesis placement (Figure 5). Because the NobelGuide system primarily controls the vertical and horizontal implant position but not the rotational implant position, nonengaging angulated abutments (Nobel Biocare) must be used. An acrylic resin jig (GC Pattern Resin, GC America, Inc) between the anterior straight multiunit abutment and posterior angulated abutment is necessary for proper abutment orientation transfer from extraoral preparation to intraoral setting (Figures 6 and 7). An all-resin prosthesis can be prefab-

ricated with temporary copings (Nobel Biocare) (Figure 8); however, one or both distal temporary copings may not be included in the prosthesis and will usually be picked-up and incorporated into the prosthesis intraorally at the time of prosthesis placement.

When the planned distal implants are angulated less than 30°, as in the described patient situation, the use of an angulated multiunit abutment is not warranted. Under such circumstances, guided adjustable abutments (Nobel Biocare) that are nonangulated vertically can be used. The advantages of using guided abut-

ments include the elimination of the time-consuming temporary coping pick-up process and the possibility of definitive prosthesis placement at the time of surgery.

Three guided anchor pins (Nobel Biocare) were planned in a tripod configuration between teeth Nos. 5 and 7, Nos. 7 and 10, and Nos. 10 and 12 (Figures 4A and 4B). The data were then sent digitally to a laboratory (3D Pro-cera Software Planning program) for fabrication of a stereolithographic surgical template (Nobel Biocare) (Figure 9) and a duplicate denture.

The stereolithographic surgical template and the duplicate denture were made of a light-sensitive resin; therefore, they are sensitive to moisture and ultraviolet (UV) light and when not in use must be kept in a dry and dark location, such as a UV-protective plastic bag in conjunction with a moisture absorber.

Laboratory Phase

Working Cast. The surgical template contained metallic sleeves (guided sleeve and anchor pin sleeve, Nobel Biocare) that corresponded to the location and the inclination of the planned implants

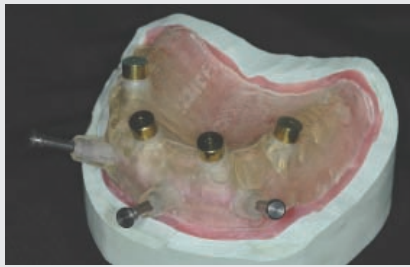

Figure 10—The maxillary working cast.

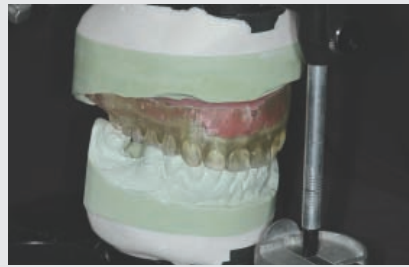

Figure 11—The working cast was mounted in an articulator using the duplicate denture.

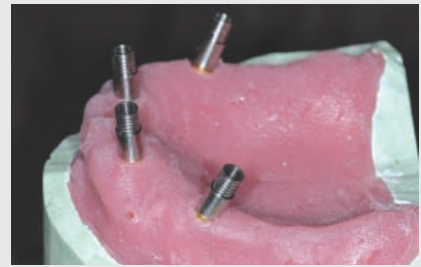


Figure 12—Guided titanium temporary copings (silver) and guided laboratory abutments (gold) were connected to the implant replicas in the working cast for prosthesis fabrication.

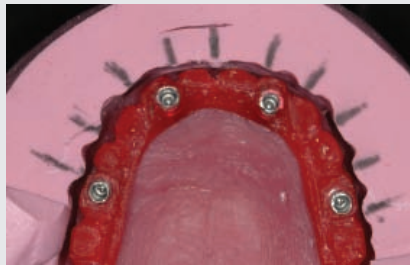

Figure 13—The silicone matrix was used as the guide to form an acrylic resin pattern of the fixed complete denture titanium framework.

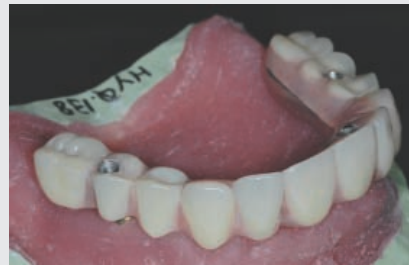

Figure 14—The definitive titanium-resin fixed complete denture was fabricated before surgery.

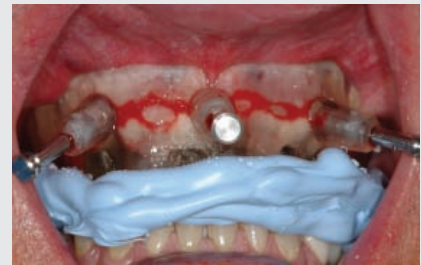

Figure 15—The surgical template was secured with the surgical occlusion index and anchor pins.

and guided anchor pins. To fabricate the maxillary working cast, the implant replicas (Nobel Biocare) were mounted in each of the metal sleeves in the surgical template using guided cylinders with unigrip pins (Nobel Biocare). The anchor pins were then inserted into the anchor pin sleeves and secured with utility wax. A silicone-based material (GI Mask, Coltène/Whaledent Inc) was applied on the intaglio surface of the surgical template and trimmed to expose the replicas and anchor pins. The working cast was then made with dental die stone plaster (Modern Materials Die-Keen Green, Heraeus Kulzer, Inc) (Figure 10) and mounted in an articulator, using the duplicate denture opposing the mandibular cast (Figure 11).

Prosthesis. A silicone matrix (Lab-Putty, Coltène/Whaledent Inc) of the duplicate denture was made on the working cast. Guided titanium temporary copings (Nobel Biocare), guided laboratory abutments (Nobel Biocare), and guided laboratory screws (Nobel Biocare) were connected to implant replicas in the working cast (Figure 12). The silicone matrix was used as the guide to form a pattern of the fixed complete denture titanium framework using autopolymerizing acrylic resin (GC Pattern Resin) (Figure 13). The resin pattern was sent to the laboratory (Nobel Biocare) where the titanium framework was milled. The definitive titanium-resin prosthesis was completed on the working cast

where fit and occlusion were verified (Figure 14). A surgical occlusion index (Exabite II NDS, GC America, Inc) was made between the surgical template and the opposing cast on the articulator to provide accurate seating of the surgical template during the surgery.

Surgical Phase

Before surgery, the surgical template was soaked in a disinfecting solution (Cidex Opa, Johnson & Johnson) for 12 minutes at room temperature, rinsed thoroughly with sterile water, and air-dried quickly without using heat to prevent its deformation. After local anesthetic administration, the surgical template was positioned using the surgical occlusion index. The 1.5 mm × 20 mm

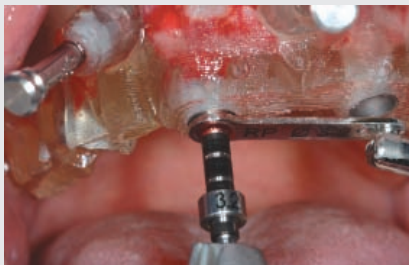

Figure 16—An implant osteotomy was made with a twist drill through the drill guide. The drill guides are available in different sizes to facilitate sequential osteotomy.

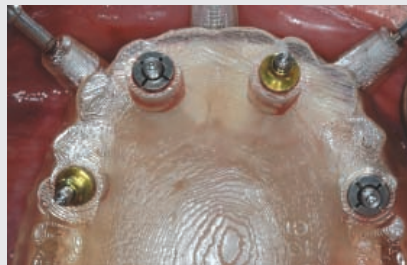


Figure 17—Implant placement was accomplished using the computer-guided template. Note the template abutments connected to the implants on teeth Nos. 7 and 12 to help stabilize the surgical template during osteotomy of the implants on teeth Nos. 5 and 10.

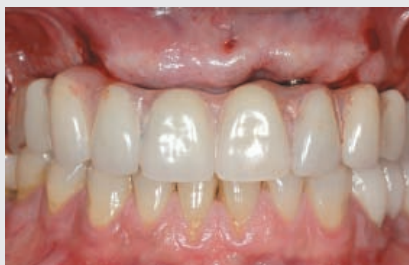

Figure 18—The definitive prosthesis immediately after implant placement.

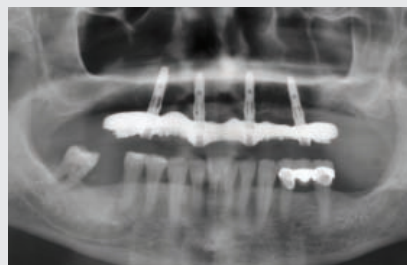

Figure 19—Panoramic radiograph of the definitive prosthesis immediately after implant placement.

twist drill (Nobel Biocare) was used for osteotomy of the guided anchor pins (Nobel Biocare) and the pins were inserted to secure the surgical template onto the maxilla (Figure 15). After the surgical occlusion index was removed, the first implant osteotomy (tooth No. 7) was made to completion using the appropriate sequence of drilling guides (Nobel Biocare) and twist drills in accordance with the manufacturer's protocol (Figure 16). After the implant was placed with an insertion torque of 45 Ncm, the template abutment (Nobel Biocare) was connected to the implant for additional stability of the surgical template. The remaining implants were placed in an alternate position order (teeth Nos. 12, 5, and 10 respectively) (Figure 17).

After removal of the surgical template, the guided abutments (Nobel Biocare) were inserted between the implants and the prosthesis before the placement of the prefabricated definitive prosthesis. The self-adjusting abutments (Nobel Biocare) are designed to compensate for vertical discrepancies (z-axis) up to 0.4 mm; however, it should be noted that misfits also can occur in the horizontal (x-axis) and/or rotational (y-axis) directions,^{17,18} which cannot be compensated for by the guided abutments. After the fit of the prosthesis was radiographically verified, the guided abutment screws (Nobel Biocare) were torqued down with 35 Ncm, and the occlusion was adjusted (Figures 18 and 19).

Postoperative Care

Appropriate antibiotic and analgesic were prescribed for postoperative use. The patient was instructed not to brush, but to rinse the implants gently with 0.12% chlorhexidine gluconate (Peridex, Procter & Gamble) for 3 weeks. A liquid diet was prescribed for the first 2 weeks and a soft diet for the duration of the implant healing phase (4 months) was recommended.

Conclusion

Computer-guided implant treatment with the All-on-Four immediate-function concept allows clinicians to plan optimal implant positions and accurately execute the plan. Well distributed implant positions translate to a biomechanically sound prosthesis supported by the least number of implants. While additional steps are involved, they are mostly laboratory procedures that eventually help expedite the clinical procedures. ©

Acknowledgment

The authors would like to thank Nobel Biocare for partial support in the treatment of the presented case, but declare no financial interests in the products depicted.

References

1. Salama H, Rose LF, Salama M, et al. Immediate loading of bilaterally splinted titanium root-form implants in fixed prosthodontics—a technique reexamined: two case reports. *Int J Periodontics Restorative Dent.* 1995;15:344-361.
2. Schnitman PA, Wohrle PS, Rubenstein JE, et al. Ten-year results for Branemark implants immediately loaded with fixed prostheses at implant placement. *Int J Oral Maxillofac Implants.* 1997;12:495-503.
3. Tarnow DP, Emtiaz S, Classi A. Immediate loading of threaded implants at stage 1 surgery in edentulous arches: ten consecutive case reports with 1- to 5-year data. *Int J Oral Maxillofac Implants.* 1997;12:319-324.

4. Randow K, Ericsson I, Nilner K, et al. Immediate functional loading of Branemark dental implants. An 18-month clinical follow-up study. *Clin Oral Implants Res.* 1999;10:8-15.
5. Jaffin RA, Kumar A, Berman CL. Immediate loading of dental implants in the completely edentulous maxilla: a clinical report. *Int J Oral Maxillofac Implants.* 2004;19:721-730.
6. Krekmanov L, Kahn M, Rangert B, et al. Tilting of posterior mandibular and maxillary implants for improved prosthesis support. *Int J Oral Maxillofac Implants.* 2000;15:405-414.
7. Zampelis A, Rangert B, Heijl L. Tilting of splinted implants for improved prosthodontic support: a two-dimensional finite element analysis. *J Prosthet Dent.* 2007;97(suppl 6):S35-S43.
8. Marchack CB, Moy PK. The use of a custom template for immediate loading with the definitive prosthesis: a clinical report. *J Calif Dent Assoc.* 2003; 31:925-929.
9. van Steenberghe D, Glauser R, Blomback U, et al. A computed tomographic scan-derived customized surgical template and fixed prosthesis for flapless surgery and immediate loading of implants in fully edentulous maxillae: a prospective multicenter study. *Clin Implant Dent Relat Res.* 2005;7(suppl 1):S111-S120.
10. Becker W, Doerr J. Three-dimensional software for fabrication of a surgical template and final implant-supported restoration for a fully edentulous maxilla: a case report. *Compend Contin Educ Dent.* 2005;26:802, 804-807.
11. Balshi SF, Wolfinger GJ, Balshi TJ. Surgical planning and prosthesis construction using computer technology and medical imaging for immediate loading of implants in the pterygomaxillary region. *Int J Periodontics Restorative Dent.* 2006;26:239-247.
12. Kan JY, Rungcharassaeng K, Oyama K, et al. Computer-guided immediate provisionalization of anterior multiple adjacent implants: surgical and prosthodontic rationale. *Pract Proced Aesthet Dent.* 2006;18:617-623.
13. Kupeyan HK, Shaffner M, Armstrong J. Definitive CAD/CAM-guided prosthesis for immediate loading of bone-grafted maxilla: a case report. *Clin Implant Dent Relat Res.* 2006;8:161-167.
14. Malo P, Rangert B, Nobre M. "All-on-Four" immediate-function concept with Branemark System implants for completely edentulous mandibles: a retrospective clinical study. *Clin Implant Dent Relat Res.* 2003;5 Suppl 1:2-9.
15. Malo P, Rangert B, Nobre M. All-on-4 immediate-function concept with Branemark System implants for completely edentulous maxillae: a 1-year retrospective clinical study. *Clin Implant Dent Relat Res.* 2005;7(suppl 1):S88-S94.
16. Malo P, de Araujo Nobre M, Lopes A. The use of computer-guided flapless implant surgery and four implants placed in immediate function to support a fixed denture: preliminary results after a mean follow-up period of thirteen months. *J Prosthet Dent.* 2007;97(suppl 6): S26-S34.
17. Tan KB, Rubenstein JE, Nicholls JI, et al. Three-dimensional analysis of the casting accuracy of one-piece, osseointegrated implant-retained prostheses. *Int J Prosthodont.* 1993;6:346-363.
18. Jemt T. In vivo measurements of precision of fit involving implant-supported prostheses in the edentulous jaw. *Int J Oral Maxillofac Implants.* 1996;11:151-158.

Product References

Products: All-on-4 with NobelGuide system (30° multiunit abutments, nonengaging guided Ti temporary copings, guided anchor pins, guided sleeves, guided anchor pin sleeves, implant replicas, guided cylinder with unigrip pins, guided titanium temporary copings, guided laboratory abutments, guided laboratory screws, guided twist drill, guided drill guide, template abutment, guided abutments, self-adjusting abutments) NobelSpeedy Replace, 3D Procera Software Planning program

Manufacturer: Nobel Biocare
Location: Yorba Linda, California
Phone: 800.993.8100
Web site: www.nobelbiocare.com

Products: Hygenic Temporary Dental Stopping, GI Mask, Lab-Putty
Manufacturer: Coltène/Whaledent Inc
Location: Cuyahoga Falls, Ohio
Web site: www.coltenwhaledent.biz

Products: GC Pattern Resin, Exabite II NDS
Manufacturer: GC America, Inc
Location: Alsip, Illinois
Phone: 800.323.7063
Web site: www.gcamerica.com

Product: Die-Keen Green
Manufacturer: Heraeus Kulzer, Inc
Location: Armonk, New York
Phone: 800.4311785
Web site: www.heraeus-kulzer-us.com

Product: Cidex Opa
Manufacturer: Johnson & Johnson
Location: Irvine, California
Phone: 888.783.7723
Web site: www.jnj.com